

# Analgesia for Total Hip and Knee Arthroplasty: A Review of Lumbar Plexus, Femoral, and Sciatic Nerve Blocks

MaCalus V. Hogan, MD, Richard E. Grant, MD, and Larry Lee, Jr., MD

## Abstract

Use of peripheral nerve blocks (PNBs) during lower extremity surgery has evolved. In this article, we review the pertinent anatomy and the literature concerning the advantages and disadvantages of both PNBs and traditional methods of postoperative analgesia (neuraxial and patient-controlled) for total hip arthroplasty and total knee arthroplasty.

We conclude that use of PNBs for total hip and total knee arthroplasty compares favorably with traditional methods of postoperative analgesia. As use of PNBs becomes more widespread, understanding their risks and benefits will be of great value to orthopedic surgeons.

Proper management of postoperative pain is essential in delivering quality care to orthopedic surgery patients. In orthopedics, pain management is paramount, as its outcomes affect hospital and patient costs, length of hospital stay, and time to patient remobilization.<sup>1</sup> Lower extremity operations, such as total hip arthroplasty (THA) and total knee arthroplasty (TKA), are common procedures, and both generate a substantial amount of postoperative pain.<sup>2</sup> Up to 50% of patients who undergo such procedures grade their pain as severe immediately after surgery and report that the pain becomes significantly worse during rehabilitation.<sup>3</sup> Perhaps most important, pain management contributes significantly to overall patient satisfaction after such procedures.

Dr. Hogan is Resident Physician, Department of Orthopaedic Surgery, University of Virginia Health System, Charlottesville, Virginia.

Dr. Grant is Professor, Department of Orthopaedic Surgery, University Hospitals of Cleveland, Case Western Medical Center, Cleveland, Ohio.

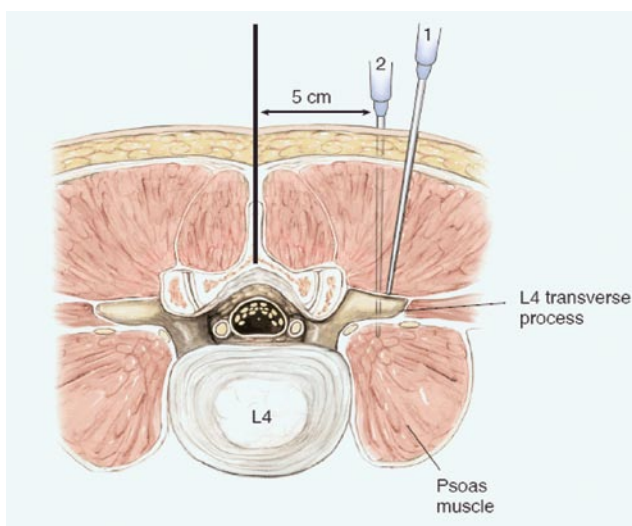
Dr. Lee is Pain Medicine Fellow, Department of Anesthesiology, Tri-Institutional Pain Fellowship of Weill Cornell New York Presbyterian Hospital, New York, New York.

Address correspondence to: MaCalus V. Hogan, MD, Department of Orthopaedic Surgery, University of Virginia Health System, PO Box 800159, Charlottesville, VA 22908-0159 (tel, 434-243-0265; e-mail, macalushogan@gmail.com).

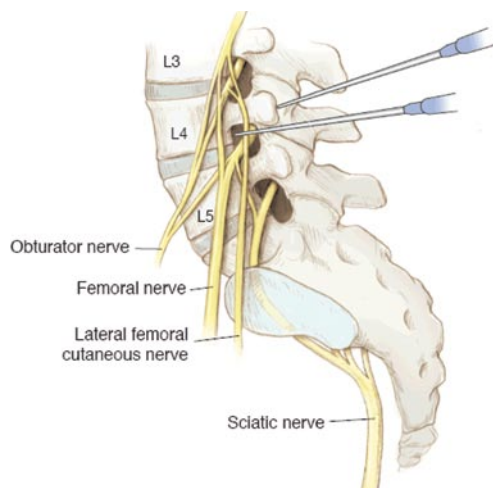
*Am J Orthop.* 2009;38(8):E129-E133. Copyright, Quadrant HealthCom Inc. 2009. All rights reserved.

Anesthetic and analgesic relief after THA and TKA traditionally has been provided through neuraxial (spinal or epidural) techniques, along with intravenous patient-controlled analgesia (PCA) using opioids. These approaches provide substantial anesthesia and analgesia, respectively, often of several hours' duration. However, the side effects of these techniques, and of the opioids administered, make their use somewhat undesirable.<sup>2,3</sup> These drawbacks have led to a shift toward redefining the effectiveness and utility of regional anesthesia, specifically, of peripheral nerve blocks (PNBs) in intraoperative anesthesia and postoperative analgesia.

Development and implementation of PNBs for THA and TKA anesthesia and analgesia evolved from an understanding of the sensory innervations to the hip and knee. The afferent information of the hip and knee is carried largely by the branches of the lumbar plexus (LP) and sacral plexus (SP).<sup>2</sup> The LP includes the ventral divisions of the first 4 lumbar nerves: the femoral nerve (FN, L2–L4), the obturator nerve (L2–L4), and the lateral femoral cutaneous nerve (L2–L3), with some input from the 12th thoracic nerve. The LP provides sensory information to



**Figure 1.** Lumbar plexus block (axial view): psoas compartment block. L4–L5 level of spine is marked. Line is drawn 5 cm off midline, toward side of operative extremity, and needle is introduced until L4 transverse process is contacted (needle 1). Stimulator needle is redirected inferiorly and deep to L4 transverse process (needle 2) until quadriceps contraction is observed. Then, anesthetic is introduced, and indwelling catheter is placed for continuous delivery of medication. Copyright 2009, Anita Impagliazzo.



**Figure 2.** Lumbar plexus block (sagittal view): relationship of lumbar plexus branches to stimulating needle during psoas compartment block. Copyright 2009, Anita Impagliazzo.

parts of the abdomen, anterior thigh, and medial malleolus. Blockade of the sciatic nerve (SN) is also of importance, as it comes from the SP and includes the ventral branches of L4–L5 and SP (S1–S3).<sup>4</sup> The SN goes on to provide sensory innervation to the posterior regions of the thigh and knee and to some parts of the leg and foot.<sup>5</sup>

A working knowledge of the sensory distribution of the lower limb helps one understand how PNBs can be useful in managing pain after lower extremity procedures. Unfortunately, these blocks traditionally have been overlooked as anesthetic choices, as many anesthesiologists had no experience in using these techniques, and orthopedic surgeons lacked an understanding of the patient benefits they offered.<sup>4</sup>

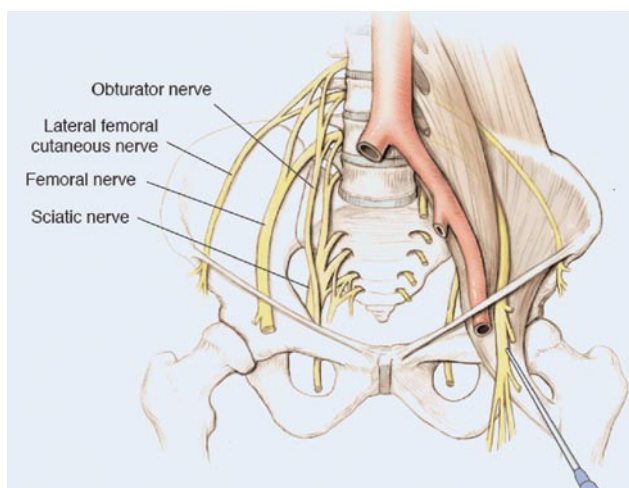
We believe that a clear understanding of the anatomy of the pertinent nerve innervation of the lower limb, the technical and procedural aspects of block delivery, and the advantages and disadvantages of both PNBs and traditional methods of postoperative analgesia (ie, spinal or epidural blocks) is of great importance. In this article, we review these factors and their significance in the delivery of LPBs, FNBs, and SNBs for anesthesia and analgesia of orthopedic postoperative pain.

## MATERIALS AND METHODS

We reviewed the literature for the technical and procedural specifications needed to perform these blocks and for the reported outcomes. We then compared our search results with those for spinal or epidural anesthesia for THA and TKA pain management. Details regarding equipment and medications, time needed, and associated complications of the PNBs were also gathered.

### Nerve Block Techniques

LPBs, FNBs, and SNBs are the most useful of the lower extremity nerve blocks.<sup>5,6</sup> Over the years, several techniques have been described for each of these blocks. Single-injection techniques were developed first. Their use was deemed beneficial, but when used alone they usually provided only several



**Figure 3.** Femoral nerve block. Needle is inserted lateral to femoral arterial pulse at level of inguinal ligament and introduced until quadriceps response is elicited. Local anesthetic alone or with indwelling catheter can be placed. Copyright 2009, Anita Impagliazzo.

hours of pain relief. In 1946, Ansbro<sup>7</sup> pioneered use of the continuous-catheter technique to increase duration of the analgesic effect. The single-injection and continuous-catheter theories are the basis for the PNB techniques that have evolved.

### Anatomical Considerations of LPBs for THA

LPBs provide adequate anesthesia and postoperative analgesia for THA.<sup>3</sup> The LP consists of the ventral rami of the nerve roots from L1 to L4, along with some contribution from the 12th thoracic nerve root. It contributes a variable amount of sensory information to the hip region.<sup>2</sup> The anatomical basis of LPBs is that the LP is located amid the psoas, quadratus lumborum, and iliacus muscles (see Figure 1). This location gave birth to 2 blockade approaches—the inguinal perivascular (“3-in-1”) block, developed by Winnie and colleagues,<sup>8</sup> and the psoas compartment block, described and later modified by Chayen and colleagues.<sup>9</sup>

The psoas compartment LPB is used for THA. The technique was originally described as a single injection of the LP, which was assumed to be located in the substance of the psoas muscle.<sup>4</sup> Through cadaver studies, it was later observed that, though the femoral and lateral femoral cutaneous branches lay within psoas muscle, the obturator in many cases lay within its own muscular plane in close proximity to the other 2 nerves.<sup>4,10</sup> Given its location, the obturator nerve was often missed during single-injection administration.<sup>2</sup> The indwelling catheter, or continuous psoas compartment block (CPCB), provides continuous anesthetic delivery to the LP.<sup>4</sup> The relationship of the LP to the stimulating needle used for block placement is depicted in Figure 2.

### Anatomical Considerations of FNBs and SNBs for TKA

The FNB was originally described by Labat.<sup>11</sup> The FN is the largest branch of the LP, forming from the posterior branches of L2–L4. It innervates the anterior thigh and quadriceps

**Table. Comparison of Advantages and Disadvantages of Neuraxial Anesthesia and Peripheral Nerve Blocks in Patients Undergoing Total Hip and Total Knee Arthroplasty**

Type of Analgesia	Delayed Incision Time	Advantages	Disadvantages	Pertinent Anatomical Landmarks
Neuraxial (spinal or epidural)	↑	Decreased blood loss Decreased need for transfusion Decreased risk for deep vein thrombosis <sup>c</sup>	Postoperative nausea and vomiting, urinary retention, severe hypotension, respiratory depression Risk for hematoma formation <sup>d</sup>	Spinous process of L4/L5
Lumbar plexus block <sup>a</sup> (psoas compartment block)	↑ <sup>b</sup>	Decreased blood loss Safe use in patients receiving thromboprophylaxis Reduced postoperative opioid requirements Increased mobilization time Shortened hospital stay Minimal side effects (nausea and vomiting, urinary retention, severe hypotension, respiratory depression) Faster emergence time compared with general anesthesia alone	Chance of block failure when PNB training is minimal Risk for improper needle placement Piercing of aorta or inferior vena cava Low risk for total spinal anesthesia Low risk for renal subcapsular hematoma Low risk for psoas hematoma formation in patients receiving anticoagulation therapy Epidural extension of anesthesia	Spinous and transverse process of L4 iliac crest Posterior superior iliac spine
FNB <sup>a</sup>	↑ <sup>b</sup>	Decreased blood loss Safe use in patients receiving thromboprophylaxis Reduced postoperative opioid requirements Earlier independent ambulation Shortened hospital stay Minimal side effects (nausea and vomiting, urinary retention, severe hypotension, respiratory depression)	Chance of block failure when PNB training is minimal Low risk for intravascular injection Rare risk for hematoma formation	Femoral triangle Inguinal ligament Femoral artery pulsations
FNB <sup>a</sup> /posterior SNB combination	↑ <sup>b</sup>	Decreased blood loss Safe use in patients receiving thromboprophylaxis Reduced postoperative opioid requirements Earlier independent ambulation Decreased analgesic nursing intervention Shortened hospital stay Minimal side effects (nausea and vomiting, urinary retention, severe hypotension, respiratory depression)	Chance of block failure when training in PNB administration is inadequate Low risk for intravascular injection (FNB) Rare risk for hematoma formation Risk for dysesthesias (SNB)	Greater trochanter of femur Posterior superior iliac spine

Abbreviations: PNB, peripheral nerve block; FNB, femoral nerve block; SNB, sciatic nerve block.

<sup>a</sup>Continuous-catheter technique.

<sup>b</sup>When performed in regional anesthesia block area by anesthesiologist with experience in PNB delivery.<sup>14</sup>

<sup>c</sup>Guidelines for use in patients receiving prophylactic anticoagulation therapy must be closely followed.<sup>18</sup>

<sup>d</sup>Risk in patients receiving thromboprophylaxis.<sup>4</sup>

muscle, along with the medial aspects of the calf and medial malleolus. The nerve passes below the inguinal ligament tracking between the psoas and iliacus muscles, just lateral to the femoral artery (Figure 3). This serves as the basis for the FNB, as the nerve can be blocked and catheterized at the level of the inguinal ligament.<sup>4</sup>

The SN emerges from the SP and has L4–L5 and S1–S3 anterior divisions. It carries the sensory information of the posterior thigh and of much of the leg and foot below the knee. This explains the usefulness of adding the SNB to an FNB for TKA. The SN passes from the pelvis through the sacrosacral foramen, below the piriformis muscle. It then tracks through the tuberosity of the ischium and greater trochanter of the femur and becomes superficial at the level of the gluteus maximus. From that point, the nerve travels down the posterior thigh.<sup>4</sup>

Although the SNB was developed by Labat,<sup>11</sup> Dalens and colleagues<sup>12</sup> concluded that the best block approaches for pediatric patients are the lateral and the posterior. The posterior approach is most often used. In this approach, the patient is placed in the lateral decubitus position with the to-be-blocked extremity up, flexed, and resting on the lower, more dependent extremity. A line is drawn from the greater trochanter to the posterior superior iliac spine, which is then bisected by a line drawn perpendicularly from the point over the middle of the gluteus muscle.<sup>4</sup> A single-injection block provides effective analgesia, particularly for posterior knee pain, after TKA.<sup>5</sup>

## DISCUSSION

Pain management after THA or TKA is a major challenge. Fifty percent of THA patients and 60% of TKA patients experience severe pain.<sup>3,13</sup> If not appropriately managed, such pain can delay the start of physical therapy and be a decisive factor in the success of rehabilitation.<sup>13</sup> Traditionally, PCA, spinal or epidural analgesia using narcotics, and/or local anesthetics were used to provide postoperative pain relief.<sup>3</sup> However, research has shown that a multimodal approach, including preemptive use of medication (cyclooxygenase 2 inhibitors, nonsteroidal anti-inflammatory drugs), must be taken for proper pain management after such procedures.<sup>1</sup> Regional anesthesia has become an efficacious adjunct to this approach, with PNBs leading the way.

In the past, lower extremity PNBs were seldom the anesthetic procedure of choice for patients undergoing total joint replacement, primarily because of anesthesiologists' lack of experience in performing these procedures.<sup>4</sup> One study concluded that many anesthesiology residency programs do not include PNB rotations in their curricula.<sup>10</sup> Such training is paramount because the time it takes to deliver such blocks decreases significantly with experience.<sup>14</sup> In recent years, however, single-injection and continuous PNBs have become part of the orthopedic postoperative analgesic approach, as they have been shown to optimize patient outcomes, satisfaction, and rehabilitation while minimizing complications and reducing costs and length of hospital stay.<sup>1</sup> Horlocker and colleagues<sup>14</sup> recently reported development of a "total joint analgesic pathway" that can be

safely used in elderly patients with significant comorbidities, specifically those with cardiopulmonary disease and obesity. Early data indicate uncomplicated and shortened hospital courses for these patients as well.<sup>14</sup> Compared with other regional anesthesia and analgesic methods, lower extremity nerve blocks offer patients many benefits and therefore have become accepted and recommended for use in lower limb surgery.<sup>2,15</sup>

Each of the reviewed nerve block techniques has complications. LPBs carry a risk for epidural or subarachnoid injection when the needle is introduced improperly. There is also the risk that the aorta and/or inferior vena cava will be pierced. Both outcomes can be prevented by performing frequent aspirations to ensure that no cerebrospinal fluid or blood is drawn during block administration. A more serious complication of LPB is hematoma formation. Although very rare, cases of psoas hematoma have been reported. Klein and colleagues<sup>16</sup> reported hematoma formation associated with supratherapeutic anticoagulation using enoxaparin. Weller and colleagues<sup>17</sup> reported psoas hematoma formation in 2 patients with traumatic catheter placement. Each FNB and SNB combination has minimal complications. SNBs uncommonly cause self-limiting dysesthesias, and FNBs carry a very low risk of intravascular injection or hematoma formation.<sup>4</sup>

The true benefits of PNB emerge when these procedures are compared with traditional spinal or epidural anesthesia and PCA methods (Table). PNB techniques reduce postoperative nausea and vomiting<sup>18</sup> and are not associated with the urinary retention problems that often plague patients who receive neuraxial blocks and other standard analgesic techniques.<sup>6</sup> Although neuraxial anesthesia does decrease blood loss and transfusion needs in THA patients, it carries the well-known risk for life-threatening spinal hematoma formation and severe neurologic dysfunction.<sup>19</sup> Lower extremity blocks can be safely used in patients who receive anticoagulation therapy, which is known to increase the risk for hematoma formation in patients undergoing spinal anesthesia.<sup>4</sup> Unlike spinal, epidural, and patient-controlled analgesia, PNBs have not been reported to cause severe hypotension or respiratory depression.<sup>20</sup> Moreover, PNBs reduce opioid requirements and blood loss after THA and TKA.<sup>4,5</sup> Turker and colleagues<sup>6</sup> concluded that CPCB provided sufficient intraoperative and postoperative analgesia with minimal complications after hip surgery. This was supported by Capdevila and colleagues,<sup>3</sup> who stated that CPCB provided "optimal analgesia" after THA with very few block failures and side effects.

## CONCLUSIONS

The rate of complications with PNBs, administered appropriately by an experienced anesthesiologist, is comparable to that with traditional methods.<sup>6</sup> But the value of PNBs goes beyond these immediate and obvious patient benefits. PNBs improve immediate patient mobilization and reduce length of hospital stay and rehabilitation time.<sup>20</sup> Moreover, regional anesthesia techniques, completed before surgery in separate induction rooms, have proved to reduce anesthesia-control

time.<sup>21</sup> These outcomes make it all the more feasible that broader use of PNBs could increase hospital efficiency and reduce health care costs. As use of PNBs evolves, it is imperative that orthopedic surgeons and anesthesiologists have a working knowledge of the anatomy, of the procedural aspects of block administration, and of the benefits and complications associated with these blocks.

### AUTHORS' DISCLOSURE STATEMENT AND ACKNOWLEDGMENTS

The authors report no actual or potential conflict of interest in relation to this article.

The authors thank Anita Impagliazzo Medical Illustration and Design for contributing to this work.

### REFERENCES

- Chelly JE, Ben-David B, Williams BA, Kentor ML. Anesthesia and postoperative analgesia: outcomes following orthopedic surgery. *Orthopedics*. 2003;26(8 Suppl):S865-S871.
- Stevens RD, Van Gessel E, Flory N, Fournier R, Gamulin Z. Lumbar plexus block reduces pain and blood loss associated with total hip arthroplasty. *Anesthesiology*. 2000;93(1):115-121.
- Capdevila X, Macaire P, Dadure C, et al. Continuous psoas compartment block for postoperative analgesia after total hip arthroplasty: new landmarks, technical guidelines, and clinical evaluation. *Anesth Analg*. 2002;94(6):1606-1613.
- Dilger JA. Regional anesthesia: lower extremity nerve blocks. *Anesthesiol Clin North Am*. 2000;18(2):319-340.
- Allen HW, Liu SS, Ware PD, Nairn CS, Owens BD. Peripheral nerve blocks improve analgesia after total knee replacement surgery. *Anesth Analg*. 1998;87(1):93-97.
- Turker G, Uckunkaya N, Yavascaoglu B, Yilmazlar A, Ozcelik S. Comparison of the catheter-technique psoas compartment block and the epidural block for analgesia in partial hip replacement surgery. *Acta Anaesthesiol Scand*. 2003;47(1):30-36.
- Ansbro FP. A method of continuous brachial plexus block. *Am J Surg*. 1946;71:716-722.
- Winnie AP, Ramamurthy S, Durrani Z. The inguinal paravascular technique of lumbar plexus anesthesia: the "3-in-1 block." *Anesth Analg*. 1973;52(6):989-996.
- Chayen D, Nathan H, Chayen M. The psoas compartment block. *Anesthesiology*. 1976;45(1):95-99.
- Chelly JE, Greger J, Gebhard R, Hagberg CA, Al-Samsam T, Khan A. Training of residents in peripheral nerve blocks during anesthesiology residency. *J Clin Anesthesiol*. 2002;14(8):584-588.
- Labat G. *Regional Anesthesia: Its Techniques and Clinical Application*. Philadelphia, PA: Saunders; 1924.
- Dalens B, Tanguy A, Vanneville G. Sciatic nerve blocks in children: comparison of the posterior, anterior, and lateral approaches in 180 pediatric patients. *Anesth Analg*. 1990;70(2):131-137.
- Singelyn FJ, Deyaert M, Joris D, Pendeville E, Gouverneur JM. Effects of intravenous patient-controlled analgesia with morphine, continuous epidural analgesia, and continuous three-in-one block on postoperative pain and knee rehabilitation after unilateral total knee arthroplasty. *Anesth Analg*. 1998;87(1):88-92.
- Horlocker TT, Kopp SL, Pagnano MW, Hebl JR. Analgesia for total hip and knee arthroplasty: a multimodal pathway featuring peripheral nerve block. *J Am Acad Orthop Surg*. 2006;14(3):126-135.
- Capdevila X, Biboulet P, Morau D, et al. Continuous three-in-one block for postoperative pain after lower limb orthopedic surgery: where do the catheters go? *Anesth Analg*. 2002;94(4):1001-1006.
- Klein S, D'Ercole F, Greengrass RA, Warner DS. Enoxaparin associated with psoas hematoma and lumbar plexopathy after lumbar plexus block. *Anesthesiology*. 1997;87(6):1576-1579.
- Weller RS, Gerancher JC, Crews JC, Wade KL. Extensive retroperitoneal hematoma without neurologic deficit in two patients who underwent lumbar plexus block and were later anticoagulated. *Anesthesiology*. 2003;98(2):581-585.
- Borgeat A, Ekatothramis G, Schenker CA. Postoperative nausea and vomiting in regional anesthesia: a review. *Anesthesiology*. 2003;98(2):530-547.
- Horlocker TT. Thromboprophylaxis and neuraxial anesthesia. *Orthopedics*. 2003;26(2 Suppl):S243-S249.
- Chelly JE, Greger J, Gebhard R, et al. Continuous femoral blocks improve recovery and outcome of patients undergoing total knee arthroplasty. *J Arthroplasty*. 2001;16(4):436-445.
- Williams BA, Kentor ML, Williams JP, et al. Process analysis in outpatient knee surgery: effects of regional and general anesthesia on anesthesia-controlled time. *Anesthesiology*. 2000;93(2):529-538.

---

*This paper will be judged for the Resident Writer's Award.*

---